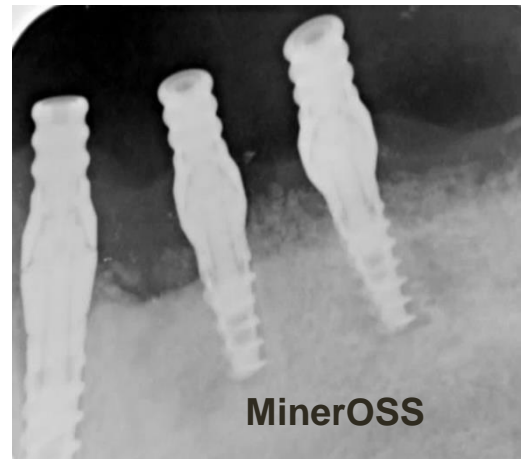
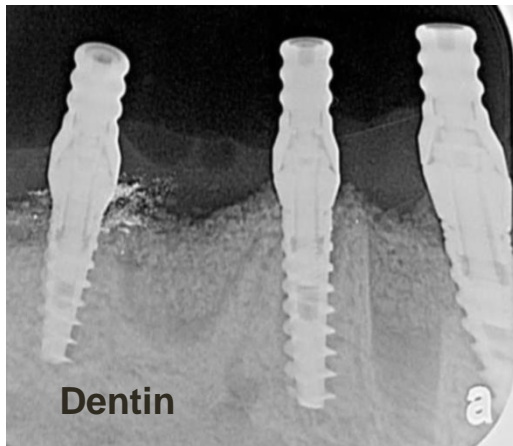
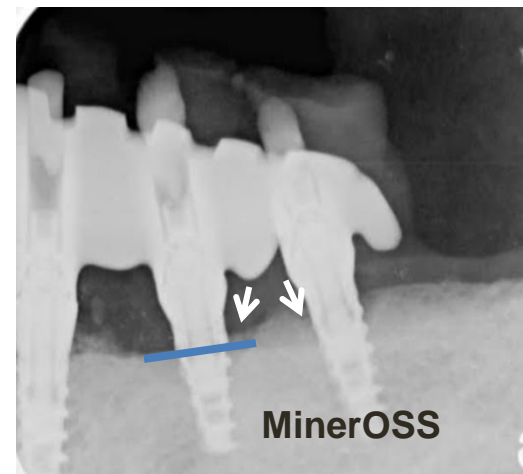
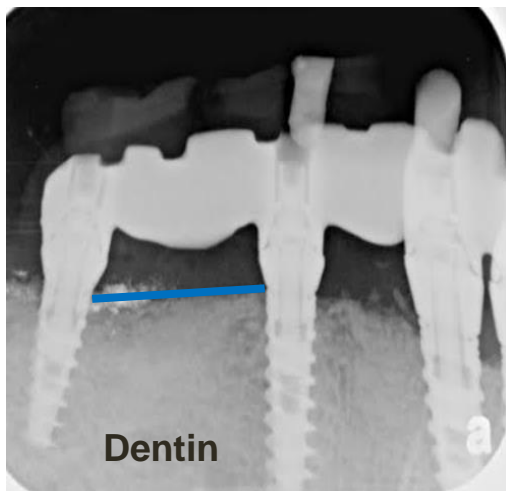


Advanced perio case for grafting and implants – dentin graft and minerOSS comparison (part 2)

Extraction sites grafted with Autologous Dentin in the right side while MinerOss on the left side of the mandible. Ridge level and bone density was compared across the two grafting options after 18 months.



On day of grafting



Blue line represents bone level. Arrows represent areas of resorption

18 months after grafting Dentin graft preserved bone level and density while the MinerOSS side presented resorption and bone level reduction